

PATIENT

Jerry Maidelis

SPECIES

Feline

BREED

DMH

SEX

Male Neutered

AGE

13 years

WEIGHT

13.75lbs

INTERPRETED BY

Maggie Machen
Lamy, DVM
DACVIM (Cardiology)

IMAGING PERFORMED BY

Pamela Harrigan,
RDMS

HOSPITAL NAME

Mass Veterinary
Specialty Services

REFERRING VET

Dr. Masloski

INVOICE

21038

DATE

9/15/21

PRESENTING CLINICAL SIGNS

History: Jerry is referred to evaluate a heart murmur heard in July. His thyroid level at that time was normal. No coughing or respiratory issues. He is eating well with normal activity. The family has not noted any concerning issues. CV/RESP: NSR, grade I-II/VI murmur noted best on sternum, PSS, lung fields clear, compressible thorax. BP: 110mmHg x 5. *No sedation.

ECHOCARDIOGRAM FINDINGS

2D, m-mode, color flow and Doppler imaging is available.

Left ventricle: The LV diameter is normal with adequate myocardial function. The LV wall thicknesses are largely normal with mild septal thickening. There is a diffusely hyperechoic endocardium consistent with fibrosis. The papillary muscles are mildly remodeled and hyperechoic.

Left atrium: The left atrium is borderline normal. No obvious spontaneous contrast or thrombi seen.

Mitral valve: The mitral valve is normal in structure and mobility. No obvious systolic anterior motion is seen. No MR.

Aortic valve/Aorta: The aortic valve is mildly thickened. Normal aortic outflow velocity; laminar flow. Trace aortic insufficiency.

Right ventricle: Normal right ventricular diameter and morphology indicating no overt evidence of pulmonary arterial hypertension.

Right atrium: The right atrium is normal in dimension.

Tricuspid valve: The tricuspid valve appears normal with trace tricuspid regurgitation.

Pulmonic valve/Pulmonary artery: The pulmonic valve is normal in morphology and mobility. No pulmonic insufficiency. Normal RVOT velocity; laminar flow.

Pericardium/other: No pericardial or pleural effusion noted. No obvious cardiac masses.

Heart rhythm: ECG reveals a sinus rhythm with an average HR of 170bpm.

2-Dimensional Measurements

Ao diam (cm)	1.1
LA diam (cm)	1.4
LA:Ao (Swe)	1.3
IVS thickness (cm)	0.43
LVID diastole (cm)	1.6
PW thickness (cm)	0.43
LVID systole (cm)	0.56
FS (%)	57

Doppler Measurements

PV Vmax (m/s)	0.76
AoV Vmax (m/s)	1.1
MR Vmax (m/s)	NA
TR Vmax (m/s)	NA
TR PG (mmHg)	NA

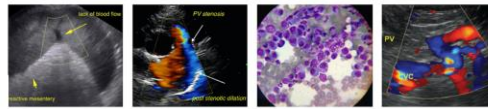
INTERPRETATION OF THE FINDINGS

HCM is a rule out diagnosis, once hypertension and hyperthyroid disease are ruled out. In this normotensive euthyroid cat, primary disease is suspected. It is worth mentioning that a focal septal thickening may or may not reflect early cardiomyopathy and monitoring for progression is advised; a normal variant is also possible. No cause for the murmur is identified, making it likely physiologic in origin.

Prognosis is open, due to the highly variable rates of progression with subclinical feline cardiomyopathy.

RECOMMENDATIONS

- Given these findings, no medications are indicated.



PATIENT

Jerry Maidelis

- Monitor BP and T4 every 6 months.
- Anesthetic risk is considered mild, however judicious IV fluid rates are advised to avoid fluid overload. Additionally, drugs that stimulate heart rate should be avoided unless clinically necessary (glycopyrrolate, atropine). A reasonable protocol includes opioid/benzodiazepine premedication, propofol induction, isoflurane maintenance.
- Risk for complication with steroid use typically follows LA dilation, which in this case is low. That being said, any cat can experience unexpected signs of intolerance and monitoring of RR/RE is advised particularly in the initiation phase.
- Monitor for any clinical evidence of cardiac compromise, including respiratory changes and/or signs of a blood clot event (paralysis, neurologic changes, etc.).

SPECIES

Feline

BREED

DMH

SEX

Male Neutered

PLAN

- Recommend recheck echocardiogram in 6-12 months to screen for progression, sooner if any clinical signs arise in the interim.

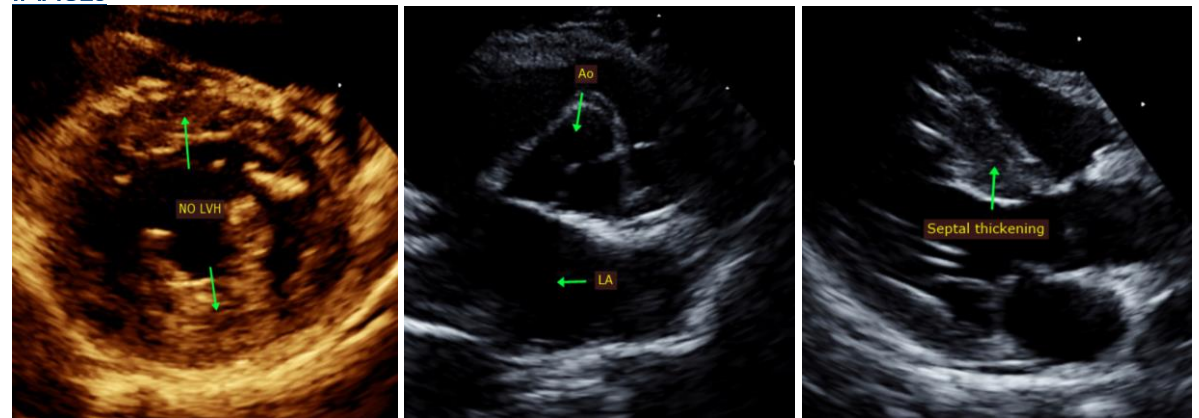
AGE

13 years

WEIGHT

13.75lbs

IMAGES



INTERPRETED BY

Maggie Machen
Lamy, DVM
DACVIM (Cardiology)

The information and recommendations provided are based on the images presented by the referring veterinarian. No evaluation can be communicated regarding pathology that was not visible in the image/video clips provided.

IMAGING PERFORMED BY

Pamela Harrigan,
RDCS

Thank you for this referral. This report was generated using transcription software, and minor dictation errors may be present. If the clinical or image interpretation does not parallel your findings or if I can be of any further assistance, please contact me.

HOSPITAL NAME

Mass Veterinary
Specialty Services

Maggie Machen Lamy, DVM
Diplomate of the American College of Veterinary Internal Medicine (Cardiology)
info@sonopath.com

REFERRING VET

Dr. Masloski

Echocardiogram performed by: Pamela Harrigan, RDCS
Pet Animal Ultrasound Service (4paus.com)

INVOICE

21038

DATE

9/15/21